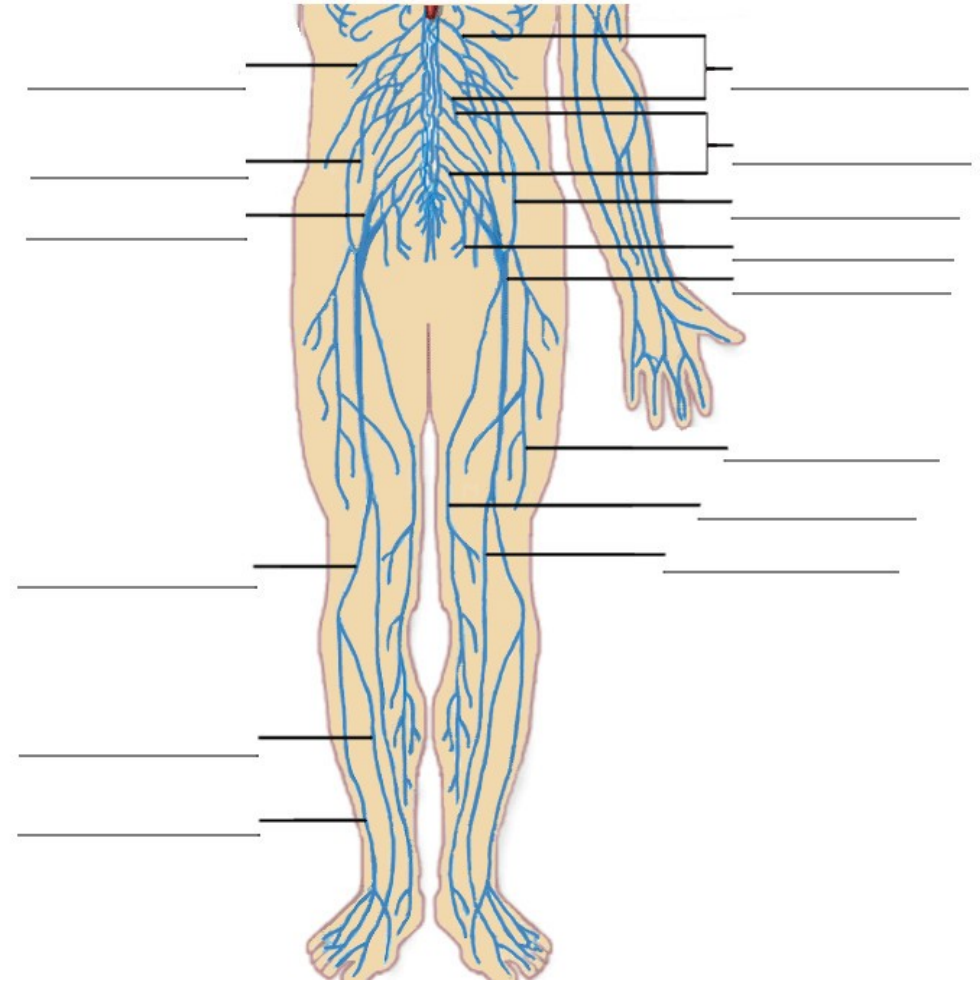
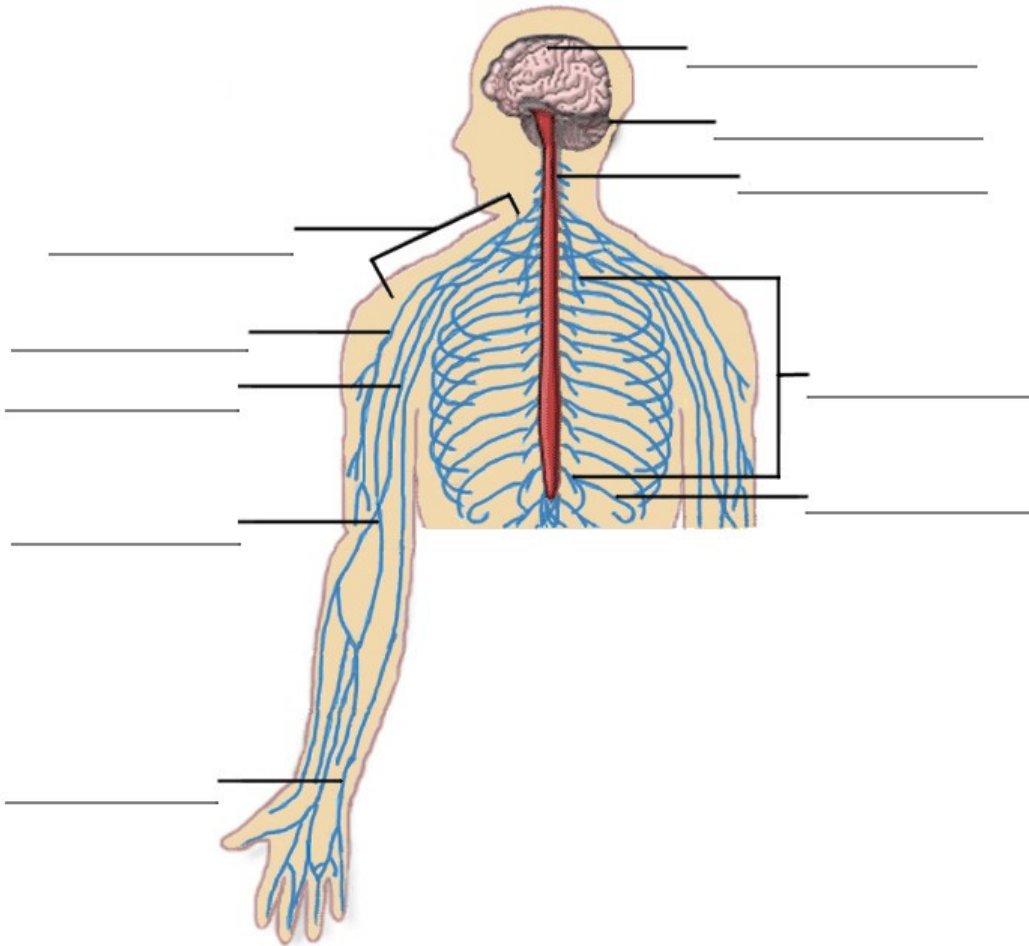


# The Nervous System



**Practice:** Name the nerves in the diagrams above, using the list below:

- |                       |                       |  |                 |                            |
|-----------------------|-----------------------|--|-----------------|----------------------------|
| Brachial plexus       | Genitofemoral nerve   | Muscular branches of the femoral nerve | Sacral plexus   | Superficial peroneal nerve |
| Cerebellum Cerebrum   | Intercostal nerves    | Musculocutaneous nerve                 | Saphenous nerve | Tibial nerve               |
| Common peroneal nerve | Iliohypogastric nerve | Obturator nerve                        | Sciatic nerve   | Ulnar nerve                |
| Deep peroneal nerve   | Lumbar plexus         | Pudendal nerve                         | Spinal cord     |                            |
| Femoral nerve         | Median nerve          | Radial nerve                           | Subcostal nerve |                            |